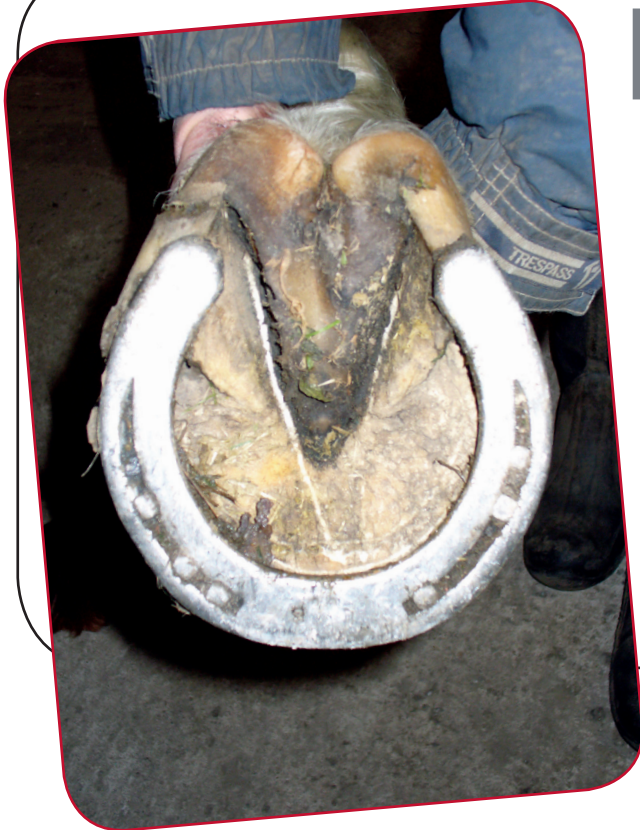



Remedial Farriery

Mechanically the foot has three main functions; shock absorption, support and grip when the limb is bearing weight. It also provides propulsion when the limb leaves the ground.

The effects of abnormal conformation or inappropriate foot trimming and farriery can lead to uneven loading, poor biomechanics, resulting in an increased risk of injury to structures in the foot and higher up the limb.

INDICATIONS FOR REMEDIAL FARRIERY

Remedial farriery is an important part of the treatment of almost all equine lameness cases. Gait abnormality or misaligned hoof (poor foot balance) may not be the direct cause of a problem but they will almost always be contributing. If not corrected, the full benefit of other forms of treatment for the lameness may not be realised.

Some of the specific conditions that can benefit from remedial farriery include:

- solar bruising
- hoof wall cracks
- caudal hoof pain
- coffin joint arthritis
- sidebone
- ringbone
- check ligament strains
- flexor tendon strains/tears
- laminitis
- angular limb deformities
- brushing
- bone spavin/osteoarthritis of the hock
- high suspensory desmitis.

The hoof wall crack shown below caused pain and lameness. Remedial farriery involved initially widening the crack, prior to fitting a bar shoe and applying a stabilising plate across the gap.



KEY POINTS

- Remedial farriery is an important part of the treatment of many lameness cases.
- Abnormal foot conformation, overgrowth or hoof distortion will increase the risk of injury to structures in the foot and higher up the leg.
- The success of remedial farriery requires a team effort between vet and farrier.

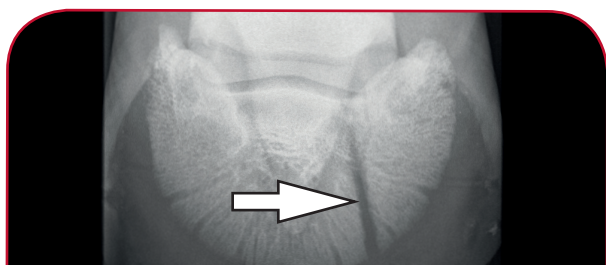
Investigation of foot lameness

When a horse is presented for poor performance or lameness, the vet will take a full history before observing the patient at the walk and trot on a straight line and circle, on a variety of surfaces.

Further investigations in the form of nerve blocks, x-rays, ultrasound and MRI may be necessary to reach a diagnosis.

A treatment plan for conditions involving the foot is formulated, normally incorporating the use of remedial farriery. Your vet will normally discuss the findings and treatment approach with your own or a specialist farrier.

The success of remedial farriery is dependent on a good team approach between vet and farrier.



X-RAY SHOWING A PEDAL BONE FRACTURE



CUFF BAR SHOE FITTED TO FOOT WITH PEDAL BONE FRACTURE

TREATMENT

Horses that have poor conformation will require foot balancing at each trim. Concussion and uneven weight bearing can influence the rate of hoof wall growth sufficient to create an imbalance over this time period.

A skilful farrier can influence the position of the foot at rest, in flight and how it lands. Each horse must be considered individually in order to select the type of shoe and trimming procedure that will be employed to improve a faulty gait.

Slow motion video assessment of the foot and limb flight can also be extremely beneficial both prior to and following corrective farriery.



HEEL RECONSTRUCTION TO CORRECT FOOT BALANCE



CONFORMATION ABNORMALITIES, SUCH AS TURNED OUT FEET, CAN LEAD TO UNEVEN HOOF GROWTH



XLEquine is a novel and exciting initiative conceived from within the veterinary profession made up of independently owned, progressive veterinary practices located throughout the United Kingdom, members of XLEquine are committed to working together for the benefit of all their clients.
© XLVet UK Ltd.

No part of this publication may be reproduced without prior permission of the publisher.

For further information contact your local XLEquine practice:

www.xlequine.co.uk

Go to www.xlequine.co.uk